

Endothelial cell infection and endotheliitis in COVID-19

Cardiovascular complications are rapidly emerging as a key threat in coronavirus disease 2019 (COVID-19) in addition to respiratory disease. The mechanisms underlying the disproportionate effect of severe acute respiratory syndrome coronavirus 2 (SARS-CoV-2) infection on patients with cardiovascular comorbidities, however, remain incompletely understood.^{1,2}

SARS-CoV-2 infects the host using the angiotensin converting enzyme 2 (ACE2) receptor, which is expressed in several organs, including the lung, heart, kidney, and intestine. ACE2 receptors are also expressed by endothelial cells.³ Whether vascular derangements in COVID-19 are due to endothelial cell involvement by the virus is currently unknown. Intriguingly, SARS-CoV-2 can directly infect engineered human blood vessel organoids *in vitro*.⁴ Here we demonstrate endothelial cell involvement across vascular beds of different organs in a series of patients with COVID-19 (further case details are provided in the appendix).

Patient 1 was a male renal transplant recipient, aged 71 years, with coronary artery disease and arterial hypertension. The patient's condition deteriorated following COVID-19 diagnosis, and he required mechanical ventilation. Multisystem organ failure occurred, and the patient died on day 8.

Post-mortem analysis of the transplanted kidney by electron microscopy revealed viral inclusion structures in endothelial cells (figure A, B). In histological analyses, we found an accumulation of inflammatory cells associated with endothelium, as well as apoptotic bodies, in the heart, the small bowel (figure C) and lung (figure D). An accumulation of mononuclear cells was found in the lung, and most small lung vessels appeared congested.

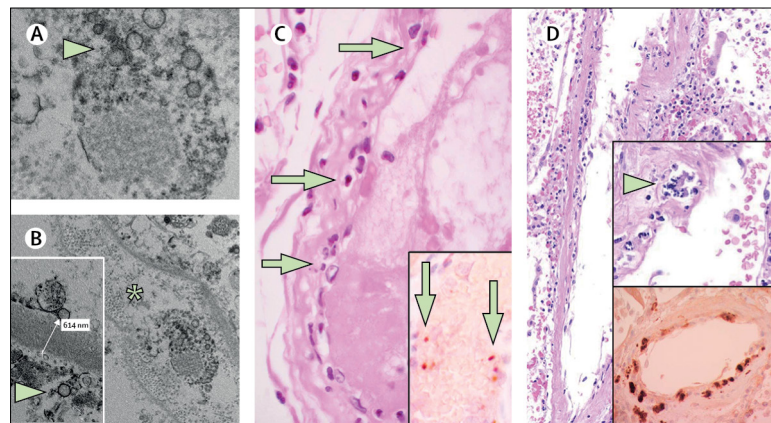


Figure: Pathology of endothelial cell dysfunction in COVID-19

(A, B) Electron microscopy of kidney tissue shows viral inclusion bodies in a peritubular space and viral particles in endothelial cells of the glomerular capillary loops. Aggregates of viral particles (arrow) appear with dense circular surface and lucid centre. The asterisk in panel B marks peritubular space consistent with capillary containing viral particles. The inset in panel B shows the glomerular basement membrane with endothelial cell and a viral particle (arrow; about 150 nm in diameter). (C) Small bowel resection specimen of patient 3, stained with haematoxylin and eosin. Arrows point to dominant mononuclear cell infiltrates within the intima along the lumen of many vessels. The inset of panel C shows an immunohistochemical staining of caspase 3 in small bowel specimens from serial section of tissue described in panel D. Staining patterns were consistent with apoptosis of endothelial cells and mononuclear cells observed in the haematoxylin-eosin-stained sections, indicating that apoptosis is induced in a substantial proportion of these cells. (D) Post-mortem lung specimen stained with haematoxylin and eosin showed thickened lung septa, including a large arterial vessel with mononuclear and neutrophilic infiltration (arrow in upper inset). The lower inset shows an immunohistochemical staining of caspase 3 on the same lung specimen; these staining patterns were consistent with apoptosis of endothelial cells and mononuclear cells observed in the haematoxylin-eosin-stained sections. COVID-19=coronavirus disease 2019.

Patient 2 was a woman, aged 58 years, with diabetes, arterial hypertension, and obesity. She developed progressive respiratory failure due to COVID-19 and subsequently developed multi-organ failure and needed renal replacement therapy. On day 16, mesenteric ischaemia prompted removal of necrotic small intestine. Circulatory failure occurred in the setting of right heart failure consequent to an ST-segment elevation myocardial infarction, and cardiac arrest resulted in death. Post-mortem histology revealed lymphocytic endotheliitis in lung, heart, kidney, and liver as well as liver cell necrosis. We found histological evidence of myocardial infarction but no sign of lymphocytic myocarditis. Histology of the small intestine showed endotheliitis (endothelialitis) of the submucosal vessels.

Patient 3 was a man, aged 69 years, with hypertension who developed respiratory failure as a result of COVID-19 and required mechanical

ventilation. Echocardiography showed reduced left ventricular ejection fraction. Circulatory collapse ensued with mesenteric ischaemia, and small intestine resection was performed, but the patient survived. Histology of the small intestine resection revealed prominent endotheliitis of the submucosal vessels and apoptotic bodies (figure C).

We found evidence of direct viral infection of the endothelial cell and diffuse endothelial inflammation. Although the virus uses ACE2 receptor expressed by pneumocytes in the epithelial alveolar lining to infect the host, thereby causing lung injury, the ACE2 receptor is also widely expressed on endothelial cells, which traverse multiple organs.³ Recruitment of immune cells, either by direct viral infection of the endothelium or immune-mediated, can result in widespread endothelial dysfunction associated with apoptosis (figure D).

The vascular endothelium is an active paracrine, endocrine, and



Published Online
April 17, 2020
[https://doi.org/10.1016/S0140-6736\(20\)30937-5](https://doi.org/10.1016/S0140-6736(20)30937-5)

See Online for appendix

Submissions should be made via our electronic submission system at <http://ees.elsevier.com/thelancet/>

autocrine organ that is indispensable for the regulation of vascular tone and the maintenance of vascular homeostasis.⁵ Endothelial dysfunction is a principal determinant of microvascular dysfunction by shifting the vascular equilibrium towards more vasoconstriction with subsequent organ ischaemia, inflammation with associated tissue oedema, and a pro-coagulant state.⁶

Our findings show the presence of viral elements within endothelial cells and an accumulation of inflammatory cells, with evidence of endothelial and inflammatory cell death. These findings suggest that SARS-CoV-2 infection facilitates the induction of endotheliitis in several organs as a direct consequence of viral involvement (as noted with presence of viral bodies) and of the host inflammatory response. In addition, induction of apoptosis and pyroptosis might have an important role in endothelial cell injury in patients with COVID-19. COVID-19-endotheliitis could explain the systemic impaired microcirculatory function in different vascular beds and their clinical sequelae in patients with COVID-19. This hypothesis provides a rationale for therapies to stabilise the endothelium while tackling viral replication, particularly with anti-inflammatory anti-cytokine drugs, ACE inhibitors, and statins.⁷⁻¹¹ This strategy could be particularly relevant for vulnerable patients with pre-existing endothelial dysfunction, which is associated with male sex, smoking, hypertension, diabetes, obesity, and established cardiovascular disease, all of which are associated with adverse outcomes in COVID-19.

ZV and AJF contributed equally as first authors, and RAS, FR, and HM contributed equally as last authors. AJF reports fees from Alnylam, Amgen, AstraZeneca, Fresenius, Imedos Systems, Novartis, Pfizer, Roche, Vifor, and Zoll, unrelated to this Correspondence. MRM reports consulting relationships with Abbott, Medtronic, Janssen, Mesoblast, Portola, Bayer, NupulseCV, FineHeart, Leviticus, Baim Institute for Clinical Research, Riovant, and Triple Gene, unrelated to this Correspondence. FR has been paid for the time spent as a committee member for clinical trials, advisory boards, other forms of consulting and

lectures or presentations. These payments were made directly to the University of Zurich and no personal payments were received in relation to these trials or other activities. All other authors declare no competing interests.

Zsuzsanna Varga, Andreas J Flammer, Peter Steiger, Martina Haberecker, Rea Andermatt, Annelies S Zinkernagel, Mandeep R Mehra, Reto A Schuepbach, *Frank Ruschitzka, Holger Moch
frank.ruschitzka@usz.ch

Department of Pathology and Molecular Pathology (ZV, MH, HM), Department of Cardiology, University Heart Center (AJF, FR), Institute for Intensive Care Medicine (PS, RA, RAS), and Division of Infectious Diseases (ASZ), University Hospital Zurich, CH-8091 Zurich, Switzerland; and Department of Internal Medicine, Brigham and Women's Hospital and Harvard Medical School, Boston, MA, USA (MRM)

- 1 Zhou F, Yu T, Du R, et al. Clinical course and risk factors for mortality of adult inpatients with COVID-19 in Wuhan, China: a retrospective cohort study. *Lancet* 2020; **395**: 1054-62.
- 2 Horton R. Offline: COVID-19—bewilderment and candour. *Lancet* 2020; **395**: 1178.
- 3 Ferrario CM, Jessup J, Chappell MC, et al. Effect of angiotensin-converting enzyme inhibition and angiotensin II receptor blockers on cardiac angiotensin-converting enzyme 2. *Circulation* 2005; **111**: 2605-10.
- 4 Monteil V, Prado P, Hagelkrüys A, et al. Inhibition of SARS-CoV-2 infections in engineered human tissues using clinical-grade soluble human ACE2. *Cell* 2020; published online in press. https://www.cell.com/pb-assets/products/coronavirus/CELL_CELL-D-20-00739.pdf (accessed April 17, 2020).
- 5 Flammer AJ, Anderson T, Celermajer DS, et al. The assessment of endothelial function: from research into clinical practice. *Circulation* 2012; **126**: 753-67.
- 6 Bonetti PO, Lerman LO, Lerman A. Endothelial dysfunction - a marker of atherosclerotic risk. *Arterioscler Thromb Vas* 2003; **23**: 168-75.
- 7 Anderson TJ, Meredith IT, Yeung AC, Frei B, Selwyn AP, Ganz P. The effect of cholesterol-lowering and antioxidant therapy on endothelium-dependent coronary vasomotion. *N Engl J Med* 1995; **332**: 488-93.
- 8 Taddei S, Virdis A, Ghiadoni L, Mattei P, Salvetti A. Effects of angiotensin converting enzyme inhibition on endothelium-dependent vasodilatation in essential hypertensive patients. *J Hypertens* 1998; **16**: 447-56.
- 9 Flammer AJ, Sudano I, Hermann F, et al. Angiotensin-converting enzyme inhibition improves vascular function in rheumatoid arthritis. *Circulation* 2008; **117**: 2262-69.
- 10 Hurlimann D, Forster A, Noll G, et al. Anti-tumor necrosis factor-alpha treatment improves endothelial function in patients with rheumatoid arthritis. *Circulation* 2002; **106**: 2184-87.
- 11 Feldmann M, Maini RN, Woody JN, et al. Trials of anti-tumour necrosis factor therapy for COVID-19 are urgently needed. *Lancet* 2020; published online April 9. [https://doi.org/10.1016/S0140-6736\(20\)30858-8](https://doi.org/10.1016/S0140-6736(20)30858-8).